

# Shockwave Intravascular Lithotripsy Facilitated Percutaneous And IVUS-Guided Revascularization Of Left Main Coronary Artery Calcification . A Case Series

Bao Jun<sup>a</sup>, Li Baihong<sup>a</sup>, Chen Chonghao<sup>a</sup>, Gao Changzheng<sup>a</sup>,  
Gu xin<sup>a</sup>, Gu Jian bing<sup>b</sup>, Wang Xiao-yan<sup>a\*</sup>

<sup>a</sup>Department of Cardiology, Affiliated Hospital of Jiangnan University, Wuxi, Jiangsu, China,

<sup>b</sup>Department of Cardiology, Huishan Second People's Hospital, Wuxi Jiangsu, 214000

## \*Corresponding author:

Wang Xiao-yan,

Department of Cardiology, Affiliated Hospital of Jiangnan University, Wuxi, Jiangsu, China,

Tel: +08615301516380,

E-mail: 1807250234@qq.com.

Received Date: 21 Oct 2023

Accepted Date: 04 Nov 2023

Published Date: 09 Nov 2023

## Citation:

Wang Xiao-yan. Shockwave Intravascular Lithotripsy Facilitated Percutaneous And IVUS-Guided Revascularization Of Left Main Coronary Artery Calcification . A Case Series. Journal Of Clinical Cases 2023.

## 1. Abstract

**1.1. Background:** Percutaneous coronary intervention (PCI) techniques are evolving, but the management of coronary calcification remains a major challenge for interventional physicians, especially left main coronary artery (LMCA) calcification. Intravascular lithotripsy (IVL) is a relatively new but promising modality for treating calcified lesions, [1] So to date, calcium modification strategies could include any combination of IVL and/or RA with high pressure non-compliant balloon and cutting balloon inflations. [2] PCI of LMCA deep calcific disease (LMCA-PCI) is challenging and its large lumen is sometimes unsuitable to RA. Furthermore, there was no large randomized controlled trials in unprotected calcified LMCA IVL.

**1.2. Methods:** Nine consecutive patients with unprotected left main disease (mean syntax score of 33.5) underwent IVUS-guided IVL before stent implantation. The procedural success rate was 100% without intraoperative complications (death, stent thrombosis, target vessel revascularization).

**1.3. Results:** Nine patients underwent unprotected LMCA IVL (11.1% of ostium 22.2% of shaft 66.7% of bifurcation). 66.7% were male and the mean age was  $65.3 \pm 9.69$  years. 55.6% of patients presented with nstable agina (UA), 22.2% with acute ST-elevation myocardial infarction (STEMI) and non-ST-elevation myocardial infarction (NSTEMI) respectively. 100% of patients had IVUS imaging. There was a significant gain within LMCA in minimal lumen area (MLA) post PCI of 100% following IVL, Minimal stent area (MSA) of LMCA was most satisfactory post PCI. There were no death, angina pectoris, bleeding, embolism, and recurrent myocardial infarction during the procedure as well as at 30 days follow-up.

**1.4. Conclusions:** IVUS-guided intravascular lithotripsy as an adjuvant to LMCA-PCI appears to be deliverable effective and safe.

## 2. Key words:

Intravascular Lithotripsy Coronary Artery Calcification Intravascular Ultrasound

## 3. Introduction

IVL has been used in percutaneous revascularization of severely calcified lesions with optimum immediate results. The safety and effectiveness of vascular pretreatment with IVL for primary calcification lesions have been validated by Disrupt CAD I-IV, [3,4,5,6] but there is a dearth of LMCA calcification treated with IVL under the guidance of IVUS, which is superior to OCT (optical coherence tomography) in this setting. [7,8] Thus, we report a preliminary case series of IVL facilitated left main PCI under the guidance of IVUS.

## 4. Material and Methods

All patients were unwilling for surgery and wished to undergo a percutaneous procedure only. 5 had UA, 2 had STEMI, 2 had NSTEMI. 6 patients were males, and the mean age was 65.3 years (range 60-82 years). Major comorbidities included diabetes mellitus 3/9, hypertension 5/9, obstructive sleep apnoea (OSA) 1/9, chronic kidney disease (2/9). Ejection Fraction (EF > 55%) was normal in 9 patients (Table 1). All calcification lesions with stenosis  $\geq 50\%$  were located within left main artery of ostium, shaft or bifurcation. (Table 1) Four AMI patients were only done PTCA on occluded LAD ostium and proximal subtotal occluded LAD during emergent intervention due to left main distal bifurcated calcification, and ended up by TIMI-III flow, then IVL was performed one week later.

**Table 1.** The baseline characteristics of the 9 patients

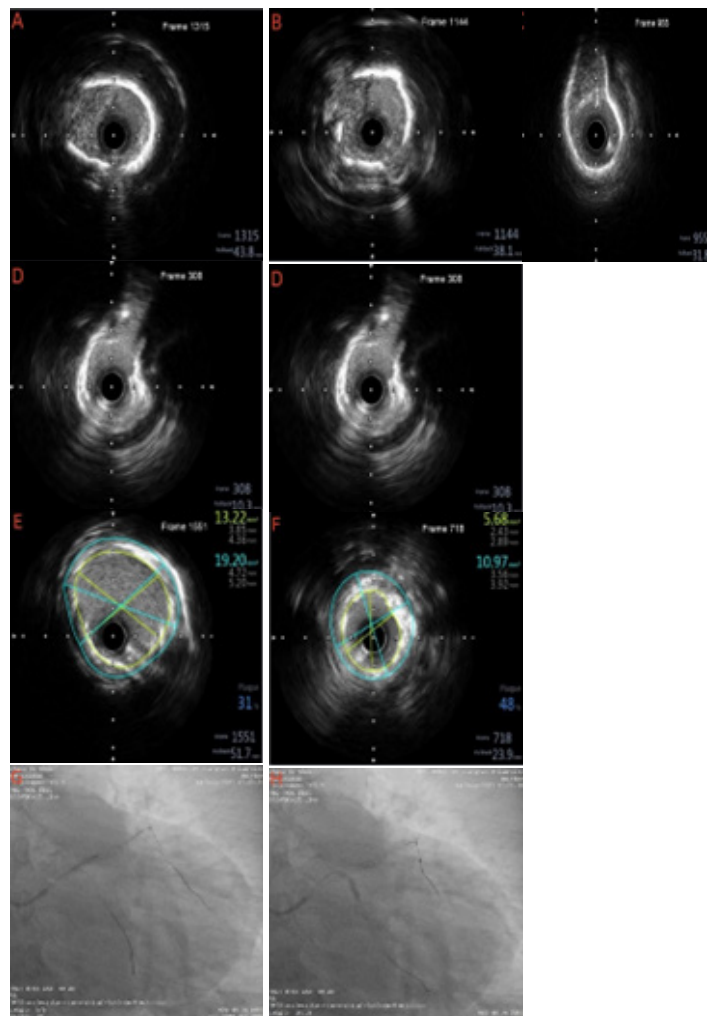
Items	N 9(100%)
Age(y)	65.3±9.69
Man	6(66.7%)
Diabetes mellitus	3(33.3%)
Hypertension	5(55.6%)
Obstructive sleep apnoea	1(11.1%)
Chronic kidney disease	2(22.2%)
EF>55%	9(100%)
UA	5(55.6%)
STEMI	2(22.2%)
NSTEMI	2(22.2%)

#### 4.1. Procedure

Coronary angiogram and IVUS showed 5 left main bifurcation of calcific LMCA disease extending into the left anterior descending artery (LAD) and the left circumflex artery (LCX). 2 shaft, 1 ostium, 3 calcific LMCA disease only extending into LAD. Intervention cardiologists performed predilatation of the lesions with noncompliant balloons according to IVUS examination, without debulking techniques (rotational atherectomy or cutting balloon). Afterward the lithotripsy balloon was advanced and several runs of IVL were applied. All cases received drug-eluting stents, which were implanted according to different technique as indicated by IVUS interrogation. In particular, left main distal bifurcation were treated with DK-crush in 2 cases, other 2 cases with coulotte technique, 1 case with crossovers tent(LAD-LM)combined DCB(LCX-LM) and 4 crossover (provisional only) cases. The stent in the left main artery was always post dilated with the proximal optimization technique (POT) via 3.5-4.5 mm noncompliant balloon according to IVUS sizing. Final IVUS was used to assess the final result.

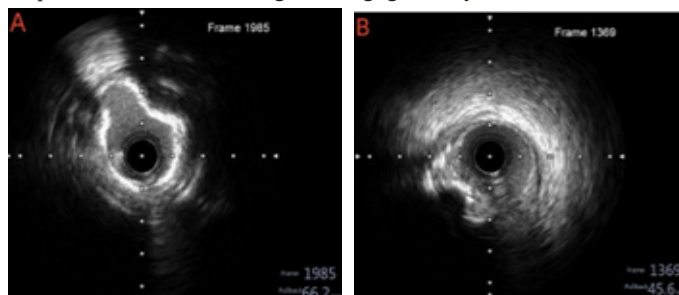
#### 5. Results

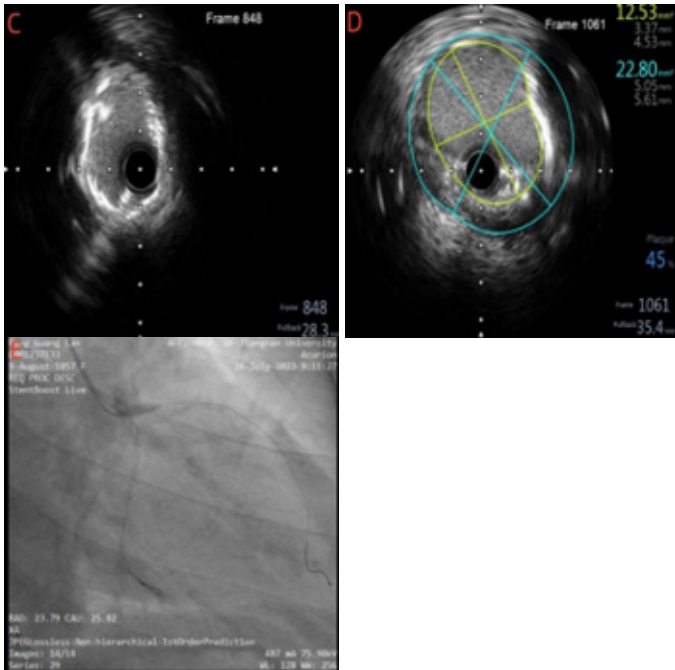
All patients were treated through the 6-7F sheath approach of the radial artery. MLA of LMCA was from  $3.48 \pm 0.91 (\text{mm}^2)$  up to  $5.28 \pm 0.67 (\text{mm}^2)$  and Plaque burden of LMCA from  $75.8 \pm 0.65\%$  down to  $71.7 \pm 0.64\%$  before and after conducted IVL evaluated by IVUS, especially for the post-dilatation with different NC balloon suitable to the blood vessel size after the implantation of the stent because of the large diameter discrepancy between LAD and LMCA. Finally, IVUS confirms good stent expansion 89.14% and MSA  $8.51 \pm 0.67 (\text{mm}^2)$  after PCI following any postdilatation or further POT of the stent. Both the IVL cross rate and procedural success rate were 100% (Table 2). Among five cases of bifurcation lesions of LM, Four cases were used shockwave balloon of  $3.0 \times 12 \text{mm}$ ,  $3.5 \times 12 \text{mm}$  from LAD to LM with 40-60 pulses, then the same balloon from LCX to LM with the left pulses respectively, and completed by double-stent procedure and one case completed by crossover stent after  $3.0 \times 12 \text{mm}$  IVL from LAD to LMCA, then DCB for LCX to LMCA (Fig. 1A, B, C, D). Four cases completed by crossover stent were treated with 3.0mm-4.0mm IVL balloon from middle LAD to LMCA, whereas LCX calcification lesion was not severe at IVUS.



**Fig.1.**(A) Distal LMCA-LAD ostium calcification;(B) Distal LMCA-LAD ostium after IVL (C) LMCA -LCXostium calcification;(D) LMCA-LCX ostium after IVL;(E) DK-crush stent LAD ostium;(F) DK-crush stent :LCX ostium;(G) LMCA-LAD IVL; (H) LMCA-LCX IVL

Two cases with calcification in the LMCA shaft and ostium were subjected to blood pressure dropped to 65-75/40-55mmHg during shockwaves, but patients didn't suffer significant symptoms and arrhythmias, possibly preconditioned by previous angina. The shock wave balloon located on LMCA shaft was filled to 4 atm with 10 pulses sent for 10s, and next to 6atm to see the expanded form of the balloon, then the pressure was quickly released (Fig. 2A, B, C, D, E). Another case of LMCA ostium was inflated to 4atm without expansion to 6atm. Through IVUS examination, all patients had calcified ring cracking, generally 2-3 cracks.





Stent implantation after NC balloon expansion of the lesions occurred according to different techniques: 4 of the 5 bifurcation lesions underwent double-stent (2 DK-crush, 2 coulotte) (Fig.1E, F), the other one underwent LAD-LMCA crossover (provisional) stent implantation, and LCX-LMCA only treated by DCB after adequate preprocessing. The other 4 cases underwent provisional stenting from the near middle of LAD to the ostium of LMCA. There were no complications such as death, angina pectoris, bleeding, embolism, and recurrent myocardial infarction during the procedure, the further hospitalization as well as at 30 days follow-up.

**Table 2.** The treatment outcomes of the 9 patients

Items	N 9(100%)
Unprotected LMCA	9(100%)
Distal	6(66.7%)
Shaft	2(22.2%)
Ostium	1(11.1%)
Mean syntax score	33.5
Pre-PCI IVUS for LMCA	9(100%)
MLA(mm <sup>2</sup> )	3.48±0.91
Plaque burden	75.8±0.65%
Pre-IVL predilatation	9(100%)
IVL balloon successful delivery	9(100%)
number of pulses applied	720
Post-IVL IVUS for LMCA	9(100%)
MLA(mm <sup>2</sup> )	5.28±0.67
Plaque burden	71.7±0.64%
Calcified ring crack	9(100%)
1	1(11.1%)
2	4(44.4%)

	3	4(44.4%)
Drug-eluting stents		9(100%)
LMCA bifurcation stenting		4(44.4%)
PCI technique		
Culotte		2(22.2%)
DK crush		2(22.2%)
Crossover stent+DCB		1(11.1%)
Cross over stent(provisional)		4(44.4%)
Post dilatation		9(100%)
Post-PCI IVUS for LM		9(100%)
MSA(mm <sup>2</sup> )		8.51±0.67
Plaque load		43.2±0.42%
MSA/average reference lumen area		89.14±4.36%

Values are expressed as n (%), mean±SD, or median (interquartile range). MLA: minimum lumen area; MSA: minimum stent area; DCB: drug-coated balloon

## 6. Discussion

Our case series demonstrate that IVUS-guided intravascular lithotripsy as an adjuvant to LM-PCI appears to be effective and safe. Traditionally, severely calcified lesions have been treated with Rotational atherectomy (RA). However, RA is usually not suitable to left main diseases due to its large diameter [9] and cutting balloon is not indicated in cases with severe calcifications due to the risk of entrapment. In China, RA burr size above 2.0mm is sometimes uneasy to obtain, especially those in diameter of 2.5mm, and require greater vascular accesses (up to 10F), which is prone to complications of femoral artery puncture. RA presents a higher in-procedure complications such as slow-flow/no-flow, dissection, perforation and other complications due to the steep learning curve and training for the team of RA. [10] Since the patients with LMCA disease had ischemic preconditioning symptoms such as chest pain, which increased the degree of tolerance during PCI. In addition, their cardiac function is relatively good, which may also be one of the important reasons for tolerance. [11] The intravascular imaging of LMCA disease was suitable for IVUS rather than OCT examination. [12] IVL had been demonstrated as adjuvant measure in LMCA-PCI appears to be an effective and well-tolerated alternative with adequate outcomes over 12-months follow-up, [13] so much more cases and longer follow-up requires confirmation of our results. Shock wave balloon treatment of LMCA calcification was a better choice, and sometimes thoracotomy could be avoided.

## 7. Fund Project:

Supported by the Project of Jiangsu Commission of Health (ZDA2020023), Project of Wuxi Municipal Health Commission (J202103), Project of Wuxi Municipal Science and Technology Commission (N20202019) and Medical industry combined research project of Wuxi Science and Technology Administration (5332207ZKJS).

## References

1. Barbato E, Shlofmitz E, Milkas A, et al. State of the art: evolving concepts in the treatment of heavily calcified and undilatable coronary stenoses - from debulking to plaque modification, a 40-year-long journey. *EuroIntervention*. 2017; 13(6): 696-705.
2. HILL J M, KEREIAKES D J, SHLOFMITZ R A, et al. Intravascular lithotripsy for treatment of severely calcified coronary artery disease. *J Am Coll Cardiol*, 2020; 76(22): 2635-2646
3. BRINTON T J, ALI Z A, HILL J M, et al. Feasibility of shockwave coronary intravascular lithotripsy for the treatment of calcified coronary stenoses. *Circulation*, 2019; 139(6): 834-836.
4. ALI Z A, NEF H, ESCANED J, et al. Safety and effectiveness of coronary intravascular lithotripsy for treatment of severely calcified coronary stenoses: the disrupt CAD II study[J]. *Circ Cardiovasc Interv*, 2019; 12(10): e008434.
5. HILL J M, KEREIAKES D J, SHLOFMITZ R A, et al. Intravascular lithotripsy for treatment of severely calcified coronary artery disease. *J Am Coll Cardiol*, 2020; 76(22): 2635-2646.
6. SAITO S, YAMAZAKI S, TAKAHASHI A, et al. Intravascular lithotripsy for vessel preparation in severely calcified coronary arteries prior to stent placement - primary outcomes from the Japanese disrupt CAD IV study. *Circ J*, 2021; 85(6): 826-833.
7. Ali ZA, Karimi Galougahi K, Nazif T, et al. Imaging-and physiology-guided percutaneous coronary intervention without contrast administration in advanced renal failure: a feasibility, safety, and outcome study. *Eur Heart J*, 2016; 37(40):3090-3095.
8. Mariani J Jr, Guedes C, Soares P, et al. Intravascular ultrasound guidance to minimize the use of iodine contrast in percutaneous coronary intervention: the MOZART (minimizing contrast utilization with IVUS guidance in coronary angioplasty) randomized controlled trial. *JACC Cardiovasc Interv*, 2014; 7(11): 1287-1293.
9. Sulimov DS, Abdel-Wahab M, Toelg R, et al. High-speed rotational atherectomy of the left main coronary artery: a single center experience in 50 high-risk patients *Cardiovasc Revasc Med* 2015; 16(5) : 284-289.
10. Lawton JS, Tamis-Holland JE, Bangalore S, et al. 2021 ACC/AHA/SCAI Guideline for Coronary Artery Revascularization; A Report of the American College of Cardiology/American Heart Association Joint Committee on Clinical Practice Guidelines. *Circulation*. 2022; 145:e18-e114.
11. Daneault B, Philippe G, Kirtane AJ, et al. Comparison of three year outcomes after primary percutaneous coronary intervention in patients with left ventricular ejection fraction 40% versus  $\geq 40\%$  (from the HORIZONS AMI Trial) [J] *Am J Cardiol* 2013 111(1):1220
12. Chatterjee A, Leeser MA, Hillegass WB. Intravascular ultrasound of normal left main arteries: Insights for stent optimization and standardization[J]. *Catheter Cardiovasc Interv*, 2014, 93(2):239-240.
13. Raymundo OS, Rosa A AS, Melisa SÁ, et al. First-in-man reported 12-months follow-up after intravascular lithotripsy in left main percutaneous revascularization[J]. *Coronary Artery Disease*, 2021, 32(6): 586-587.